

Anatomy Lessons by the Amsterdam Guild of Surgeons. Medical Education and Art

de Bree E¹, Tsiaoussis J², Schoretsanitis G¹

Abstract

The Amsterdam Guild of Surgeons organized lessons in anatomy as part of the education of surgical trainees and surgeons. Appreciating that the acquisition of correct anatomical knowledge by regular perceptive education during dissection of the human body was essential for surgeons, in 1555 Philip II, King of Spain and Holland, gave his permission to the Amsterdam Guild of Surgeons to perform anatomical dissections on bodies of deceased humans. The anatomy instructors, called “praelectores anatomiae”, who were always academically educated medical doctors, were appointed by the guild for the teaching of anatomy. They commissioned painters to produce group portraits, with the “praelector anatomiae” delivering an anatomy lesson as the central figure. Probably the best-known of such paintings is the masterpiece of Rembrandt van Rijn (1632) “The anatomy lesson of Dr. Nicolaes Tulp”. Although these paintings are historical portraits rather than authentic pictures of an anatomical dissection, today this series of paintings of the Amsterdam Guild of Surgeons still reminds us of this essential part of the surgical training programme. While anatomy lessons on bodies of deceased humans was already an obligatory and crucial part of the medical (i.e., surgical) education in the 16th century, nowadays many medical schools unfortunately do not provide such practical anatomy lessons for their students, for whom usually only theoretical lessons and textbooks constitute the educational tools for learning human anatomy.

Key words: *Guild of surgeons; anatomy lessons; medical education; paintings*

The Amsterdam Guild of Surgeons

Surgeons were known to be already practising in the Netherlands in the 14th century, for example 1351 in Rotterdam and 1380 in Utrecht. Only from the middle of the 15th century, however, are there indications of their organization into the craft guilds for artisans that were customary in the Middle Ages in large parts of Europe. Craft guilds were occupational associations with obligatory membership, which protected the interests of the members. They were organized by the town or city council, which also acted in a supervisory capacity. In Holland it appears that surgeons’ guilds were founded in various towns in the 1460s, being recorded in Leyden in 1466, Rotterdam in 1467, and as early as 1465 in Gorkum. In Amsterdam and Middelburg guilds were not noted until 1497 and 1501, respectively [1].

Although in the Netherlands the academically educated “doctores medicinae” traditionally had surgical knowledge, they did not as a rule engage in practical surgery. On the other hand, many barbers, who were of the lower class, practised a kind of surgery, but with limited formal education. In the 16th century, a middle group was gradually formed, partly of physicians who did not wish to limit their interest to theoretical knowledge, and partly from barber-surgeons with some knowledge of medicine [1]. They joined together in a surgeon’s guild in order to define their job-related activities and to restrict those of possible rivals [2]. It is clearly apparent that the surgeons’ guilds invested in training and examination over the course of time [3,4]. Amsterdam was among the first cities in Europe where the training requirements to become a surgeon were extensively described and regulated [3]. The rules and regulations of the Amsterdam Guild of Surgeons that were issued from 1461 to 1736 were collected in the book “Privilegien, willekeuren en ordonnantien, betreffende het Collegium Chirurgicum Amstelaedamense” (1736) [5]. This book describes in detail the training and education, as well as the final examination, necessary to become a surgeon in the initial period of the Amsterdam Guild of Surgeons. After passing the final examination, the successful candidate could join the guild and practise the job of a surgeon independently [3,5]. Details of the training and examination of Amsterdam surgeons were

¹Department of Surgical Oncology, School of Medicine, University of Crete Hospital, Heraklion, Greece

²Laboratory of Anatomy, Histology and Embryology, School of Medicine, University of Crete, Heraklion, Greece

Corresponding author: de Bree Eelco, MD, PhD
Department of Surgical Oncology, University Hospital,
P.O. Box 1352, 71110 Heraklion, Greece
Tel.: +30 2810 392056 / 392382, Fax: +30 2810 392382
e-mail: debree@edu.uoc.gr

Received ; Revised ; Accepted

presented in an earlier article in this Journal [6]. Surgeons were traditionally trained in a master-mate relationship, in which the apprentice learned the job by spending, usually a 5-year period, working in a surgical office, called the “surgeon’s store” in those days, under the guidance of his master surgeon. An essential part of the surgical education was the obligatory presence of the trainees at the anatomy lessons of the guild.

Anatomy lessons and theatres

In Amsterdam the first recorded human anatomy dissection took place in about 1550 in a “dissecting room” in the old Saint Ursula Convent, the seat of the Amsterdam Guild of Surgeons at that time [7]. Appreciating that correct anatomical knowledge acquired by regular preceptive education during dissection of the human body was essential for surgeons, in 1555 Philip II, King of Spain and Holland, gave his permission to the Amsterdam Guild of Surgeons to perform public anatomy dissections [5,8]. For this purpose, the judiciary was required to place at the disposal of the guild the mortal remains of criminals who had been executed. Initially, only one body of a deceased person was anatomically dissected annually, but later the number of bodies provided for dissection was increased [8]. The dissections were performed over a period of several days and took place initially only in the winter, because of the lack of proper preservation techniques in the early period. In order to promote and regulate education in anatomy, in 1606 an “ordinance for anatomy” was issued [5,8].

In 1578, the new City Council of Amsterdam gave the guild specific permission to maintain their dissecting room above the chapel of the old convent of Saint Margaret, which had been converted into the new slaughter-house “Nieuwe of Kleine Vleeschhal” [9]. In 1619, the guild moved to the De Waag (“Weigh-House”), the former Saint Anthony Gate, where they had a small anatomy theatre. De Waag was also used as a guild room, with furniture, paintings and medical instruments. From 1639 until 1691, the surgeons again used their old quarters in the slaughter-house, and then in 1691, they finally moved to their new amphitheatre in the middle tower of De Waag [10]. The amphitheatre consisted of a series of concentric circular wooden galleries, with a rotating table in the centre (Figure 1). The first gallery, with seats, was kept for members of the City Council, inspectors of the “Collegium Medicum” and medical doctors aged over 50 years. Apart from the front row there were no seats. The second and third rows were kept for the other medical doctors, the members of the board of the guild of surgeons and master surgeons over 50 years. Rows 4, 5 and 6 were for the younger surgeons. The seventh and eighth rows were for the apprentices of the guild and the general public. The dissec-




Figure 1. Drawing of the anatomy theatre in De Waag in which dissections and anatomy lessons were conducted (1690).

tions were usually open to the general public on payment of an admission fee, in order to cover related expenses [1]. Although in 1798 the Amsterdam Guild of Surgeons was disbanded by the Napoleonic administration, the theatre in De Waag continued to be used for anatomy lessons for medical students until 1869.

The pursuit of a medical discipline, of which anatomy was a part, could not simply be left to the surgical craftsmen. It would appear from the stipulation included in the privilege of King Philip II that the dissections which were for the benefit of the surgeons, must take place ‘in the presence of, and with instruction from, expert physicians’ [1].

The “praelectores anatomiae”, who were always academically educated medical doctors, were appointed by the guild for the teaching of anatomy. Maarten Janszoon Coster was appointed the first “praelector anatomiae” of the guild in 1578 [11]. The anatomy lessons had a preceptive character in which the “praelector anatomiae” taught his students who attended the anatomy demonstration from the rows of benches in the anatomy theatre. Walking around, talking, laughing or interrupting the “praelector anatomiae” was certainly not allowed during the lessons [5,8]. There was actually no opportunity for practical education, such as apprentices or surgeons being able to take an active part in a dissection [8]. Nevertheless, these lessons offered them a unique opportunity to view the anatomy of the human body on an actual body, in addition to the anatomical textbooks. The “praelectores anatomiae” were usually considered very important people in the city. Some of them became mayors or played some other leading role in the affairs of the city.

Paintings of anatomy lessons of the Amsterdam Guild of Surgeons

It is generally recognized that the “praelectores anatomiae” commissioned painters of their day to produce a group portrait with the “praelector” as the central figure [12]. The paintings of anatomy lessons were exhibited in the guild room, which was established on the first floor of De Waag [7,8]. In 1798, the Amsterdam Guild of Surgeons was disbanded by the Napoleonic administration and the paintings came into the possession of the Surgeons' Widows Association. Although some had been sold through the years to foreign art dealers, currently the paintings of the Amsterdam Guild of Amsterdam anatomy lessons are fortunately all present in the collections of museums and institutes in the Netherlands.

A series of painters of portraits, landscapes, views of cities etc., painted this anatomy lesson in the tradition of the famous group portraits that flourished in 17th century Holland, a predominantly urban, middle-class society where the main patrons of the arts were the leading citizens of the various cities [13]. The paintings of the anatomy lessons differ from the group portraits of regents, in that the attention is clearly focused on one individual, the person conducting the lesson. This tradition started with the picture of an anatomy lesson that appeared on the title page of the book by Andreas Vesalius “De humani corporis fabrica” in 1543 [14,15]. In the 16th century it became customary to produce pictures of anatomy lessons on title pages of medical books.

The anatomy lesson of Dr. Sebastiaen Egbertsz de Vrij

The earliest known painting of an anatomy lesson in Amsterdam is “The anatomy lesson of Dr. Sebastiaen Egbertsz de Vrij”, painted by Aert Pietersz (Figure 2). Sebastiaen Egbertsz de Vrij (1563-1621) studied medicine at Leyden University until 1585 and became a general practitioner in Leyden, before being appointed “praelector anatomiae” in Amsterdam in 1595. He was subsequently appointed mayor of Amsterdam in 1606, and in 1609 became a member of the Staten-Generaal of the United Provinces of Holland [11]. Aert Pietersz was commissioned for the painting in 1601 by Egbertsz de Vrij [16]. By the time it was finished in 1603, five persons in the painting had already died as a consequence of a plague epidemic [17], from which Egbertsz de Vrij himself died eventually, several years later [11]. He is observed in the center of the painting behind the body with a pair of scissors in his right hand. The 28 master surgeons depicted look neither towards the “praelector anatomiae” nor towards the body, but in the direction of the spectator. The artist has clearly based his composition on that of the militia banquet [18].

In 1619, Thomas de Keijser composed a painting with the same title. This version of “The anatomy lesson of Dr.



Figure 2. The anatomy lesson of Dr. Sebastiaen Egbertsz de Vrij. Painting by Aert Pietersz, 1603. Amsterdam Historical Museum.

Sebastiaen Egbertsz de Vrij” clearly used another type of composition (Figure 3), in which the “praelector anatomiae”, with a high hat, gives an osteological demonstration, and only five officers of the guild are depicted [17].

The anatomy lesson of Dr. Johan Fonteijn

In 1625 and 1626, Nicolaes Elias painted “The anatomy lesson of Dr. Johan Fonteijn” (Figure 4). After he had finished his medical studies, Johan Fonteijn (1574-1628) became a general practitioner in Amsterdam and, later, a



Figure 3. The anatomy lesson of Dr. Sebastiaen Egbertsz de Vrij. Painting by Thomas de Keijzer, 1619. Amsterdam Historical Museum.



Figure 4. The anatomy lesson of Dr. Johan Fonteijn. Painting by Nicolaes Elias, 1625/26. Amsterdam Historical Museum.

“praelector anatomiae” in 1621. In 1623 he was appointed personal physician to Prince Maurits of Holland [11]. In the painting of Nicolaes Eliasz, Fonteijn is demonstrating a human skull to surgeons of the guild. Originally the painting was much bigger, with 10 master surgeons and some “college masters” depicted [17], but it was badly damaged by the fire in De Waag in 1723. During restoration it was reduced to the upper portion of the original central part. The person on the far left is from another part of the original, while the skull is also a later addition to the painting [12].

The anatomy lesson of Dr. Nicolaes Tulp

The reknowned Rembrandt van Rijn painted “The anatomy lesson of Dr. Nicolaes Tulp” in 1632 (Figure 5). Nicolaes Tulp (1593-1674) was originally trained non-academically as a surgeon, but after finishing the Latin School in Amsterdam he studied medicine at Leyden University. In 1614, he graduated with a dissertation “De cholera humida” and became a general practitioner in Amsterdam. In 1628 he was appointed “praelector anatomiae” of the Amsterdam Guild of Surgeons, while in 1622 he became an alderman and in 1653 mayor of Amsterdam. In 1641 he published his famous “Observationes medicae” [19]. In the painting, he demonstrates the dissection of the flexors of the forearm on the corpse of an executed criminal. Dr. Tulp holds forceps in his right hand, with which he is demonstrating a muscle. The identification of this muscle is a matter of dispute [20-22], which, along with other presumed mistakes in the anatomy of the dissected forearm in this masterpiece, has been discussed in medical and art-history literature for decades, in spite of which there is still no general consensus about the structures depicted in the forearm [20-22]. While most

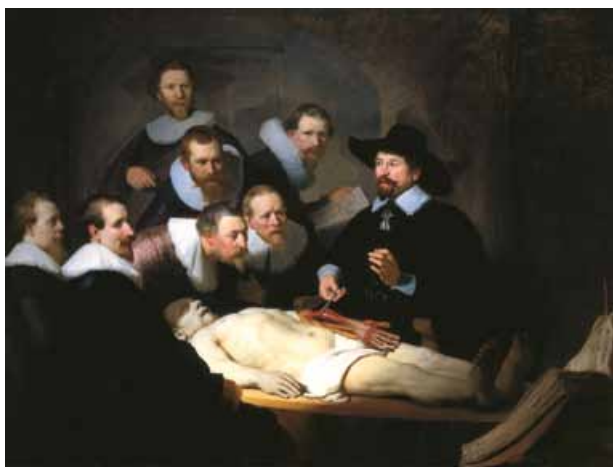

Figure 5. The anatomy lesson of Dr. Nicolaes Tulp. Painting by Rembrandt van Rijn, 1632. The Hague, Mauritshuis.

viewpoints are based on comparison of the painting with anatomical atlases, a recent dissection of the forearm of a human cadaver showed four anatomical differences compared with Rembrandt’s painting [22]. It has been suggested that the present state of the painting is not that of the original composition. In the recent restoration of the painting it was established that the person at the apex of the composition, wearing a hat, and the anatomical picture present on the roll call sheet were alterations that Rembrandt added to his original composition [12]. It was also demonstrated that in the original composition Rembrandt did not paint the right hand of the corpse, but that the right arm ended in a stump.

The anatomy lesson of Dr. Johannes Deijman

In 1656 Rembrandt van Rijn painted another lesson, “The anatomy lesson of Dr. Johannes Deijman” (Figure 6). The “praelector anatomiae”, of whom only his hands are visible, is demonstrating the meninges in a brain dissection. The instrument he is using is probably forceps or a probe. The surgeon and “collegiemeester” (assistant to the “praelector”) Gijsbert Calkoen, is watching the dissection and holds a part of the skull in his left hand [17]. The abdomen has been dissected previously. Between the “praelector” and Calkoen the lower part of another person is vaguely visible. The depiction of the position of the body is similar to that in Andrea Mantegna’s “The Lamentation” [23]. The painting in its present state is only a fragment, but a drawing of the original painting, probably placed in the guild room later than 1656, gives some idea of what it was originally like [23]. In the original painting two other persons were present on the left of Calkoen, and on the left of Deijman another three. This drawing also gives an indication of the theater, because a gallery is visible.

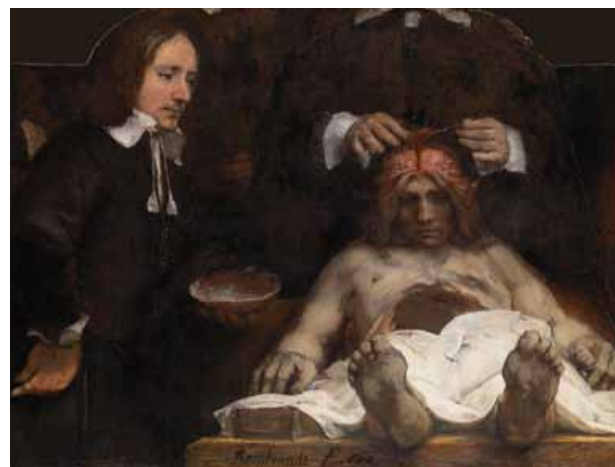

Figure 6. The anatomy lesson of Dr. Johannes Deijman. Painting by Rembrandt van Rijn, 1656. Amsterdam Historical Museum.

The anatomy lesson of Professor Frederik Ruijsch

Adriaen Backer painted “The anatomy lesson of Professor Frederik Ruijsch” in 1670 (Figure 7). The “praelector anatomiae”, with 6 guild members standing beside him, is dissecting the left groin and upper leg. In his right hand he holds a lancet. The body is that of an idealized young man, illustrating the profound change in artistic ideas. Backer obviously agreed with Jan de Bisschop’s strictures against those artists who chose to paint misshapen people instead of well-built youthful figures [24]. In the background of the painting, statues of Apollo and Aesculapius are depicted.

Another painting with the same title was made by Johan van Neck in 1683 (Figure 8), but in this version the “praelector anatomiae” is dissecting a newborn child. He is demonstrating the blood vessels in the umbilical cord and the placenta. The boy in the painting is the son of the “praelector”, Hendrik Ruijsch, holding the mounted skeleton of a newborn child [17].

The anatomy lesson of Dr. Willem Roëll

Cornelis Troost finished “The anatomy lesson of Dr. Willem Roëll” in 1728 (Figure 9). The “praelector anatomiae” is demonstrating the knee joint. Besides Dr. Roëll and several local well-known surgeons, a guild servant is seen on the left [17]. This is the only painting of an anatomy lesson in which the persons are portrayed full-length. There is a crayon drawing of the painting which suggests that the painting must originally have been bigger, with the background showing part of the anatomy theater [17].

The anatomy lesson of Professor Petrus Camper

“The anatomy lesson of Professor Petrus Camper” by Tibout Regters was finished in 1758 (Figure 10). The “praelector anatomiae” demonstrates on a head and neck specimen a dissection of the neck muscles and nerves. The composition is



Figure 7. The anatomy lesson of Professor Frederik Ruijsch. Painting by Adriaen Backer, 1670. Amsterdam Historical Museum.

That of the traditional group portrait with hardly any action, in which, in addition to Professor Camper and some local eminent surgeons, a guild servant is seen on the left [17].



Figure 8. The anatomy lesson of Professor Frederik Ruijsch. Painting by Johan van Neck, 1683. Amsterdam Historical Museum.



Figure 9. The anatomy lesson of Dr. Willem Roëll. Painting by Cornelis Troost, 1728. Amsterdam Historical Museum



Figure 10. The anatomy lesson of Prof. Petrus Camper. Painting by Tibout Regters, 1758. Amsterdam Historical Museum.

Historical portraits or authentic pictures of anatomy lessons?

All the pictures of anatomy lessons are genre paintings, commissioned portraits, and probably most of them were not actually painted in the anatomy theaters of Amsterdam. Concerning the lessons of Deijman (Figure 6) and Roëll (Figure 9) it is known from drawings that the intention of the painter was to depict the anatomy theater in the background. Only Rembrandt van Rijn's "The anatomy lesson of Dr. Nicolaes Tulp" (Figure 5) can be considered as an emblematic portrait [21,25]. It is arguable whether all the anatomy lessons that were painted depict a real contemporary anatomy demonstration. The beautiful paintings give, however, together with archival sources, good portraits of the "praelectores anatomiae" and the leading persons in the Amsterdam Guild of Surgeons at the time. From an anatomical point of view the painted lessons often do not give much information about the dissection. In the painting by Aert Pietersz (Figure 2), the body is not even dissected, in that of Thomas de Keijser (Figure 3) the "praelector" is lecturing on the vertebral column of a bare skeleton and the painting by Nicolaes Elias (Figure 5) shows only a skull with no further indication of a dissected body. In the composition of Tibout Regters (Figure 10) there is a good demonstration of anatomical structures, but the painting does not show any action. In contrast, the paintings by Rembrandt (Figures 4 and 6), Adriaen Backer (Figure 7), Johan van Neck (Figure 8) and Cornelis Troost (Figure 9) show clearly an anatomical demonstration, although in Rembrandt's "The anatomy lesson of Dr. Nicolaes Tulp" it appears that the anatomy of the dissected forearm is inaccurate [20-22]. Another feature of most of the paintings is the absence of dissecting instruments, although from archival sources it is known that many different instruments were used in Amsterdam during the anatomy demonstrations [12]. It can definitely be stated that many of the paintings of Amsterdam anatomy lessons are historical portraits, without being authentic pictures of an anatomy dissection [7].

Reflection on the contemporary anatomical lessons

Although they are more often historical portraits rather than authentic pictures of an anatomy dissection, even today this series of paintings of the Amsterdam Guild of Surgeons of anatomy lessons with portraits of the "praelectores anatomiae" reminds us of this essential part of the surgical training program. Anatomy lessons on bodies of deceased humans, although in the form of passive rather than (inter)active education, was already a compulsory and crucial part of the medical (i.e., surgical) education in the 16th century. Unfortunately, today, many medical schools

no longer provide such practical lessons in anatomy on human subjects for their students, for whom only theoretical lessons and textbooks have to suffice as the educational tools for learning human anatomy.

Anatomy teaching appears to be in decline, which is attributed to both endogenous and exogenous factors [26]. Specifically, intrinsic characteristics of anatomy, such as stereotypes regarding its nature (a traditional or even tedious subject), its inadequate evolution and the delay in adaptation of anatomy teaching for contemporary needs, and, on the other hand, exogenous factors, including the rapidly increasing number of new medical schools, the shortage of cadavers and the cost of maintaining a dissecting room, have squeezed out the traditional role of anatomy as a cornerstone of medical education.

Moreover, dissection *per se* is subject to the pressure of technology. New modalities, such as plasticized bodies, sophisticated anatomy software for personal computers and virtual dissection tables, in parallel with new educational approaches (interactive education, problem-based learning), have been proposed as alternatives to dissection [27]. The above reductions and changes in the teaching of anatomy have been shown to affect the level of qualifying doctors by lowering their clinical skills [28]. The issue of when and how anatomy should be taught, and how much, undoubtedly have a major place at the epicenter of modernization of medical curricula, and a remapping aimed at the return of students to the anatomy laboratory at multiple points during the educational process would have only positive results on the clinical abilities of young doctors [29]. This policy is most obvious and essential in the case of surgeons, interventional radiologists and all doctors who perform an invasive procedure. Finally, it needs to be underlined that the new, innovative educational tools should be integrated with learning by dissection, rather than supplanting it.

References

1. De Moulin D. A history of surgery with emphasis on the Netherlands. Dordrecht: Martinus Nijhoff; 1988.
2. Van Eeghen IH. De gilden theorie en praktijk. Bussum: Van Dishoeck; 1965.
3. Boesman T. De examens in de chirurgijnsgilden. Utrecht: Kemink en Zoon; 1942.
4. Van Lieburg MJ. De genees- en heilkunde in de noordelijke Nederlanden, gezien vanuit de stedelijke en chirurgijnsgilde ordonnanties van de 16e eeuw. Tsch Gesch Gnk Natuurw Wisk Techn 1983;6:169-84.
5. Meyer H. Privilegien, willekeuren en ordonnantien, betreffende het Collegium Chirurgicum Amstelaedamense. Amsterdam: Pieter van den Berge; 1736.

6. de Bree E, Schoetsanis G. The Amsterdam Guild of Surgeons and the training of surgeons in the early modern period. *Hell J Surg* 2018;90:205-9.
7. Baljet B. The painted Amsterdam anatomy lessons: Anatomy performances in dissecting rooms? *Ann Anat* 2000;182:3-11.
8. Nuyens BWTh. Het ontleedkundig onderwijs en de geschilderde Anatomische lessen van het Chirurgijns Gilde in Amsterdam, in de jaren 1550 tot 1798. In: Jaarverslag Koninklijk Oudheidkundig Genootschap. Amsterdam: Koninklijk Oudheidkundig Genootschap; 1928.
9. Veder WR. Het St. Anthonis Poorthuis te Amsterdam III. *Eigen Haard* 1911:292-4.
10. Veder WR. Het St. Anthonis Poorthuis te Amsterdam IV. *Eigen Haard* 1911:358-61.
11. Theissen JS. Levensberichten van professoren en lectoren. In: Brugmans H, Scholte JH, Kleintjens Ph, editors. *Gedenboek van het Athenaeum en de Universiteit van Amsterdam*. Amsterdam: Stadsdrukkerij; 1932. pp. 535-715.
12. Middelkoop NE. Groote kostelijke schilderyen, alle die de kunst der Heelmeesters aangaan. De schilderijenverzameling van bet Amsterdamse Chirurgijns Gilde. In: Middelkoop NE, Noble R Wadum J, Broos B (Eds.) *Rembrandt onder bet mes. De anatomische les van Dr. Nicolaes Tulp ontleed*. The Hague: Maurishuis; 1998. pp. 9-38.
13. Haak B. Regenten en regentessen, overliden en chirurgijns: Amsterdamse groepsportretten van 1600 tot 1835. Amsterdam: Amsterdams Historisch Museum; 1972.
14. Vesalius A. *De humani corporis fabrica, libri septem*. J Operinus, Basel; 1543.
15. Nuyens BWTh. Het ontleedkundig onderwijs en de geschilderde Anatomische lessen van het chirurgijns Gilde te Amsterdam, in de jaren 1550 tot 1798. Amsterdam: Jaarverslag Zeventigste Algemene Vergadering van bet Koninklijk Oudheidkundig Genootschap te Amsterdam; 1928.
16. Middelkoop NE. *De Anatomische Les van Dr. Deijman*. Amsterdam: Amsterdam Historical Museum; 1994.
17. Tilanus JWR. *Beschrijving der schilderijen afkomstig van bet chirurgijns-gild te Amsterdam. Met eenige historische aantekeningen omtrent bet gild, en eene nadere beschouwing der kunstwaarde der verzameling*. Amsterdam: Frederik Muller; 1865.
18. Köhler N, Levy-van Halm K, Frans Hals. *Militia Pieces*. The Hague: Gary Schwartz; 1990.
19. Thijssen EHM, Nicolaas Tulp. *Bijdrage tot de geschiedenis der geneeskunde in de zeventiende eeuw*. Amsterdam: University of Amsterdam; 1881.
20. Σχορετσανίτης ΓΝ. Το μάθημα της ανατομίας του Δρ Nicolaes Tulp. In: Σχορετσανίτης ΓΝ, editor. *Ιστορικά στοιχεία & άλλα παραλειπομένα της εξέλιξης της Ανατομικής*. Αθήνα: ΒΗΤΑ Ιατρικές Εκδόσεις; 2014. pp. 173-83.
21. Schoetsanis GN. The anatomy lesson of Dr. Nicolaes Tulp. In: Schoetsanis GN, editor. *Historical and other neglected data on the evolution of anatomic studies*. Athens: BHTA Medical Arts; 2014. pp. 173-83.
22. Schupbach W. The paradox of Rembrand's "Anatomy of Dr. Tulp." *Medical History, Supplement No. 2*. London: Wellcome Institute for the History of Medicine; 1982.
23. Ijpma FF, van de Graaf RC, Nicolai JP, et al. The anatomy lesson of Dr. Nicolaes Tulp by Rembrandt (1632): A comparison of the painting with a dissected left forearm of a Dutch male cadaver. *J Hand Surg Am* 2006;31:882-91.
24. Cetto AM. De anatomische les van Dr. Deyman. *De Kroniek van bet Rembrandthuis* 1959;13:57-62.
25. Bolten J. *Method and practice, Dutch and Flemish drawing books*. Landau: Edition PVA; 1985.
26. Heckscher WS. *Rembrandts anatomy of Dr. Nicolaas Tulp, an iconological study*. New York: New York University Press; 1958.
27. Older J. *Anatomy: A must for teaching the next generation*. *Surgeon* 2004;2:79-90.
28. Verhoeven BH, Verwijnen GM, Scherpbier AJJA, et al. An analysis of progress test results of PBL and non-PBL students. *Med Teacher* 1998;20:310-6.
29. Prince KJ, Scherpbier AJ, van Mameren H, et al. Do students have sufficient knowledge of clinical anatomy? *Med Educ* 2005;39:326-32.
30. Turney BW. Anatomy in a modern medical curriculum. *Ann R Coll Surg Engl* 2007;89:104-7.